

THE OCCURRENCE OF ASPERGILLOSIS IN FLOCK OF TURKEY POULTS

B. Kureljušić, O. Radanović, J. Kureljušić, N. Jezdimirović, D. Maslić-Strižak, R. Prodanović, V. Ivetić

Scientific Veterinary Institute of Serbia, Vojvode Toze 14, 11000, Belgrade, Republic of Serbia.

Corresponding author: branslav_kur@yahoo.com
Communication

Abstract: Aspergillosis is frequent fungal disease of different avian and mammal species, caused by infection by the fungi of genus *Aspergillus*. The disease is characterized by inflammatory changes in the respiratory system and sometimes has generalized onset when more organ systems are affected. In this paper, we examined a flock of turkey poults, 21 days old, at one farm in Serbia. Clinical signs of central nervous system in the form of ataxia, torticollis, paresis and paralysis of legs and wings were observed. The mortality rate in the flock was 7,2 %. In ten out of twelve necropsied turkey poults multiple yellowish-white granulomas, one to three millimeters in diameter on lungs were found. In nine out of twelve necropsied turkey poults solitary yellowish-white granuloma, three to five millimeters in diameter on sagittal section of the cerebrum or cerebellum were found. Mycological finding revealed fungi *Aspergillus fumigatus*. For the evaluation of histopathological changes in lung and brain and demonstration of fungal hyphae, three stain methods were used: haematoxylin-eosin (HE), Grocott methenamine silver and periodic acid Schiff (PAS) method. Microscopic examination of lung and brain has revealed the presence of granulomatous foci and caseous necrosis with surrounding region of proliferation including giant cells, macrophages, heterophils and lymphocytes and outer capsule of connective tissue. The fungal hyphae were hardly or not visible in HE stained sections, while septed and arborized hyphae were easily demonstrated by Grocott and PAS stain predominantly in central parts of granuloma. For diagnostic of mycotic infection is necessary to use different histochemical methods for evaluation of histopathological changes and detection of etiological agent, including isolation to obtain etiological diagnosis.

Key words: turkey poults, mycotic granuloma, *Aspergillus fumigatus*

Introduction

Aspergillosis is frequent, economically important, fungal disease of different avian and mammal species caused by fungi of the genus *Aspergillus*. The disease is characterized by inflammatory changes in the respiratory system and sometimes has generalized onset when more organ systems are affected. Clinical signs of aspergillosis depend upon which organ or system organ are involved and whether infection is localized or generalized. Pathomorphological substrate of this disease is mycotic granuloma (aspergiloma) which is commonly found in lungs and air sacs. Numerous reports have described encephalitic or meningoencephalitic aspergillosis in turkey poults, ducklings and chickens (Knežević and Matejić, 1996; Ivetić et al., 2003; Ozmen and Dorresteijn, 2004; Singh et al., 2009, Kureljušić et al., 2011a). Olias et al. (2010) have described a case of articular aspergillosis of hip joints in turkeys. Comparative experimental study of the susceptibility of different species of poultry to infection with *Aspergillus fumigatus* has shown that turkeys are more susceptible than chickens. Primarily, there are two forms of aspergillosis in poultry: acute and chronic. Acute aspergillosis is usually characterized by severe outbreaks in young birds and high morbidity and high mortality. The mortality rate may range from 70 to 90%. Chronic aspergillosis occurs in adult breeder birds (particularly turkeys). It is very difficult to diagnosticate this infection by clinical examination because in many cases more organ systems are affected. It is known from literature that the diagnosis of fungal infections of poultry often be placed only after histopathological examination of organs of infected poultry (Richard et al., 1984, Saif, 2008). For diagnostic of mycotic infection is necessary to use more methods including clinical examination of flock, macroscopic examination of carcasses, isolation of pathogens, as well as histochemical methods for detection tissue lesions and fungal elements. Histochemical methods which can be used are routine hematoxylin-eosin staining method, periodic acid-Schiff (PAS) and specific staining method for fungi Grocott methenamine silver method (GMS) (Ozmen and Dorresteijn, 2004). There is also a possibility to use immunohistochemical methods for direct in situ evidence of etiological agent (Jensen et al., 1997).

Materials and methods

In this paper, we examined the carcasses of 12 turkey poults, three weeks old which originated from one farm in Serbia. The mortality rate in the flock was 7,2%. Clinical examination of the flock revealed moderate depression of many turkey poults and nervous symptoms which were expressed in the form of ataxia, torticollis, paresis and paralysis of legs and wings. Food consumption was reduced leading to reduced weight gain. After necropsy, for histopathological and

mycological examination samples of lung and brain tissue were taken. Samples for histopathological analysis were fixed in 10% buffered formalin, routinely processed and embedded in paraffin blocks. Paraffin sections about 5 μm were stained with hematoxylin-eosin (HE), periodic acid Schiff (PAS) and Grocott methenamine silver (GMS) methods. Samples for mycological examination were inoculated onto Sabouraud dextrose agar and incubated at temperature of 25°C under aerobic conditions for isolation of infectious agents. To avoid bacterial contamination in the substrate was added 20 IU/ml penicillin G and 40 mg/ml streptomycin sulfate. Macroscopic and microscopic examination of colonies was performed according to *Quinn* (2002). Samples of feed and litter were also taken for mycological analysis.

Results and discussion

External examination of turkey poults carcasses indicates less feathering of the skin especially in the region of chest.

In ten out of twelve necropsied turkey poults granulomatous pneumonia with multiple yellowish-white granulomas, one to three millimeters in diameter were found (Figure 1).

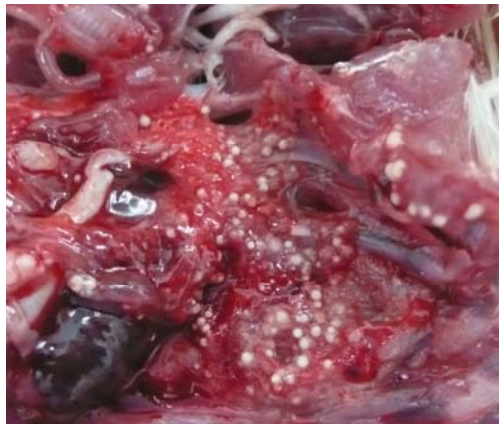

Figure 1. Lung of turkey poult, granulomatous pneumonia

In addition, multifocal granulomatous airsacculitis of thoracic and abdominal air sacs was also observed. In advanced cases of aspergillosis, the organism can sporulate on the surface of the caseous lesions and on the walls of the thickened air sacs, as evidenced by visible greenish-gray mold growth. That was also found in one case of aspergillosis in black swan (*Kureljušić et al., 2011b*), but in this case there were no such lesions. In 3 out of twelve necropsied turkey poults solitary

yellowish-white granuloma of irregular shape, three to five millimeters in diameter on sagittal section of the cerebrum or cerebellum were found (Figure 2).

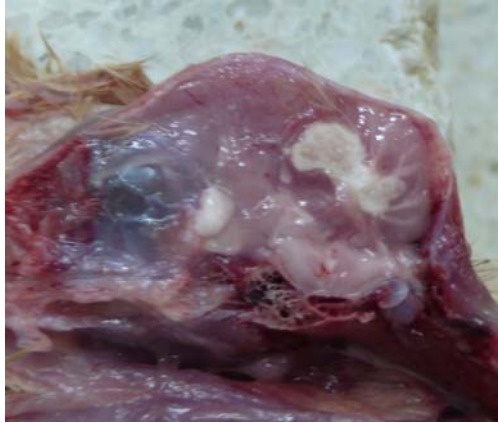

Figure 2. Brain of turkey poult, granuloma on sagittal section of cerebellum

In two out of twelve cases granulomas were found on the cranial part of the cerebrum, and in one case granuloma was on the central part of cerebellum. Data from literature indicate that granulomas caused by *Aspergillus fumigatus* (aspergilomas) usually occur in the lungs and air sacs although there are data on the occurrence of aspergilomas in the cerebellum, only in turkey poults (*Schulz, 1991; Ozmen and Dorrestein, 2004; Saif 2008, Kureljušić et al, 2011a*). Similar to our observations, the granulomas occur either in cerebrum or the cerebellum (*Saif, 2008*). Rarely, aspergillomas occur simultaneously in both parts of brain (*Saif, 2008*). In addition to this finding, in turkey poults that were necropsied, hyperemia of cerebral blood vessels was found. In other organs there were no macroscopically visible changes.

Mycological examination revealed that the ethiological agent is fungus *Aspergillus fumigatus*. Growth in the medium was observed after 24 hours, and after four days, grown colonies were white and about 2 cm in diameter. By the seventh day the colony diameter increased to 3.5 cm, and there was a color change in the central part of the colonies from blue-green to the gray-green, while the edges remained white (Figure 3). Based on macroscopic and microscopic characteristics of colonies, the culture was identified as *Aspergillus fumigatus*.



Figure 3. Growth of *Aspergillus fumigatus* on Sabouraud dextrose agar

For the evaluation of histopathological changes and demonstration of fungal hyphae, three stain methods were used: haematoxylin-eosin (HE), Grocott methenamine silver and PAS method. Histological finding in the lung and in the brain was the same. Granulomatous reactions with central caseous necrosis were observed in the HE stained slides. There was surrounding region of proliferation including giant cells, macrophages, heterophils and lymphocytes and outer capsule of connective tissue (Figure 4, Figure 5).

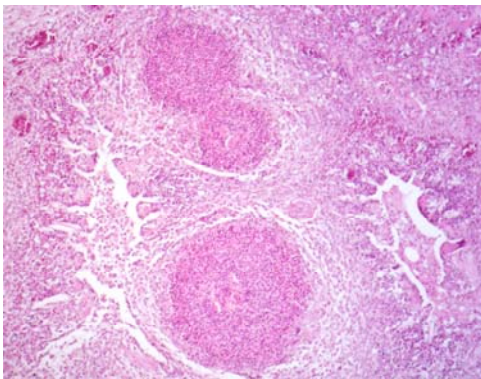


Figure 4. Lung, turkey poult, multifocal granulomatous pneumonia, HE, X200

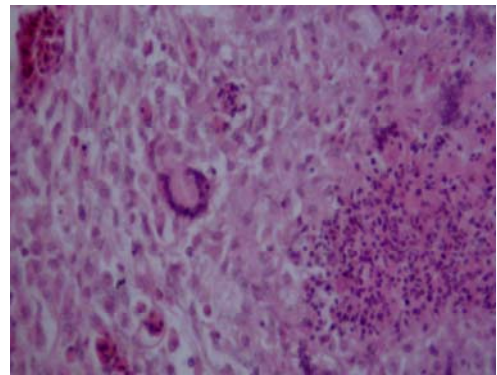


Figure 5. Lung, turkey poult, infiltrate of granuloma consist of giant cells, macrophages, heterophils and lymphocytes, HE, X400

The fungal hyphae were either hardly visible or not visible in HE slides, while septed and arborized hyphae were easily demonstrated in all samples by

Grocott methenamine silver and PAS stain, predominantly in central parts of granuloma (Figure 6, Figure 7).

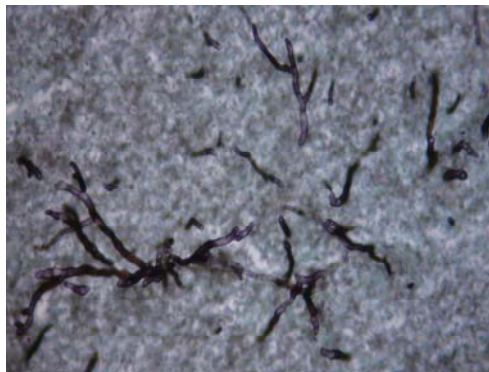


Figure 6. Brain, turkey poult, arborized and septed hyphae, Grocott, X400

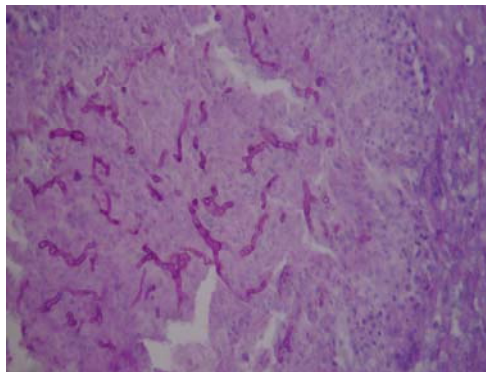


Figure 7. Lung, turkey poult, arborized and septed hyphae, PAS, X400

In some cases, in the sections of brain and lung stained by HE method, granulomatous changes were characterized only by presence of smaller or larger number of necrotic foci, which are infiltrated with macrophages, giant cells and heterophil granulocytes. These changes are described in the literature as early initial lesions (*Jensen et al., 1997*). In three out of twelve cases in HE stained sections, fungal hyphae were not apparent. Grocott and PAS methods in all twelve cases revealed septed and arborized hyphae. Thus, the specific staining methods revealed fungal hyphae even if minimal histopathological changes occurs. Based on this finding it can be assumed that the occurrence of lesions in the lung and brain depends not only on the presence of infectious agents, but also on the reaction of the immune system of the host. PAS and Grocott method are described in the literature as a very reliable method for direct visualization of the different fungal elements in tissues (*Ozmen and Dorrestein, 2004; Singh et al., 2009*).

Mycological analysis of litter revealed *Aspergillus fumigatus* while samples of feed were negative for this microorganism. It is known from literature that contaminated litter is often the source of *Aspergillus fumigatus* (*Saif 2008*).

Conclusion

Microscopic finding of typical mycotic granulomas in the lung and brain with central caseous necrosis and fungal hyphae surrounded by macrophages, giant cells, lymphocytes, heterophils and capsule of connective tissue pointed to aspergillosis. For diagnostic of mycotic infection is necessary to use more methods including clinical examination of flock, macroscopic examination of carcasses,

isolation of pathogens, as well as histochemical methods for detection of tissue lesions and fungal elements.

Acknowledgment:

This work was financed by the Ministry of Education and Science, Republic of Serbia, project number III 46009

Pojava aspergiloze u jatu ćurića

B. Kureljušić, O. Radanović, J. Kureljušić, N. Jezdimirović, D. Maslić-Strižak, R. Prodanović, V. Ivetić

Rezime

Aspergiloza je često gljivično oboljenje različitih vrsta ptica i sisara, izazvana gljivicama roda *Aspergillus*. Oboljenje se karakteriše inflamatornim promenama u respiratornom sistemu, a ponekad može da se javi u generalizovanoj formi kada je zahvaćeno više organskih sistema. U ovom radu, ispitano je jato ćurića, starosti 21 dan, na jednoj farmi u Srbiji. Kliničkim pregledom jata ustanovljeni su simptomi oboljenja centralnog nervnog sistema u formi ataksije, tortikolisa, pareze i paralize nogu i krila. Stopa mortaliteta u jatu je bila 7,2 %. Kod 10 od 12 obdukovanih ćurića na plućima su ustanovljeni multipli žuto-beli granulomi, od jedan do tri milimetara u prečniku. Kod 9 od 12 obdukovanih ćurića na sagitalnom preseku malog ili velikog mozga nađeni su pojedinačni žuto-beli granulomi, veličine od tri do pet milimetara u prečniku. Mikološkim ispitivanjem izolovana je gljivica *Aspergillus fumigatus*. Za procenu histopatoloških promena u plućima i mozgu kao i dokaz hifa gljivica, korišćene su tri histohemijske metode: hematoksilin-eozin (HE), Grocott methenamine silver (GMS) i PAS metoda. Mikroskopskim pregledom uzoraka pluća i mozga bojenih HE metodom, ustanovljeno je prisustvo granuloma sa centralnim područjem kazeozne nekroze koje je bilo okruženo sa gigantskim ćelijama, makrofagima, heterofilima, limfocitima i spoljašnjom kapsulom sačinjenom od vezivnog tkiva. Hife gljivica, kao sastavni delovi granuloma, bile su teško uočljive, a u nekim uzorcima bojenim HE metodom nisu se ni videle. Nasuprot ovome, u preparatima bojenim Grocott i PAS metodom jasno su se isticale septirane i razgranate hife u centralnim delovima granuloma.

U dijagnostici ovog gljivičnog oboljenja neophodno je primeniti više histohemijskih metoda kako za procenu histopatoloških promena tako i za dokaz uzročnika, uključujući i izolaciju u cilju postavljanja etiološke dijagnoze.

References

- IVETIĆ V., VALTER D., PAVLOVIĆ I., MILJKOVIĆ B., MASLIĆ-STRIŽAK D., ILIĆ Ž., SAVIĆ B., STANOJEVIĆ S., SPALEVIĆ LJ.(2003): Atlas bolesti živine, Naučni institut za veterinarstvo Srbije, Beograd
- JENSEN H.E., CHRISTENSEN J.P., BISGAARD M., NIELSEN O.L.(1997): Immunohistochemistry for diagnosis of aspergillosis in turkey poults, *Avian Pathology* 26, 5-18
- KNEŽEVIĆ N., MATEJIĆ M.(1996): Bolesti pernate živine, Veterinarska komora Srbije, Beograd
- KURELJUŠIĆ B., SAVIĆ B., PRODANOVIĆ R., ĐEKIĆ J., ADAMOV V., JAKIĆ-DIMIĆ D., MILJKOVIĆ B., RADANOVIĆ O., IVETIĆ V.(2011A): Primena različitih histohemijskih metoda u dijagnostici aspergiloze mozga kod ćurića, *Veterinarski glasnik* 65, 1-2, 43-50
- KURELJUŠIĆ B., PRODANOVIĆ R., KURELJUŠIĆ J., JEZDIMIROVIĆ N., RADANOVIĆ O. (2011B): Prikaz slučaja aspergiloze kod crnog labuda (*Cygnus atratus*), *Živinarstvo* 1/2, 21-26
- OLIAS P., HAUCK R., WINDHAUS H., VAN DER GRINTEN E., GRUBER A.D., HAFEZ H.M. (2010): Articular aspergillosis of hip joints in turkeys, *Avian Disease* 54, 1098-1101
- OZMEN O., DORRESTEIN M.G.(2004): Observations of aspergillosis in the brains of turkey poults using different histopathological staining techniques, *Biotechnic and Histochemistry* 79, 2, 95-99
- QUINN P.J., MARKEY B.K., CARTER M.E., DONNELLY W.J.C., LEONARD F.C.(2002): *Veterinary microbiology and microbial disease*, Blackwell Science Ltd., Iowa State University Press
- RICHARD J.L., THURSTON J.R., PEDEN W.M., PINELLO C.(1984): Recent studies on aspergillosis in turkey poults, *Mycopathologia* 87, 3-11
- SAIF Y.M.(2008): *Diseases of poultry*, twelfth edition, Blackwell Publishing, Ames, Iowa, USA
- SCHULZ L.CL.(1991): *Pathologie der Haustiere*, Teil 1, Gustav Fischer Verlag, Jena
- SINGH S., BORAH M.K., SHARMA D.K., JOSHI G.D., GOGOI R.(2009): Aspergillosis in turkey poults, *Canadian Journal of Veterinary Pathology* 33, 2, 220-221